



Treatment Modalities for Rehabilitation of Mutilated Primary Anterior Teeth

Rashi Srivastava^{1*} and Nilima Thosar¹

¹*Department of Pediatric and Preventive Dentistry, Sharad Pawar Dental College, Datta Meghe Institute of Medical Sciences (Deemed to be University), Sawangi (Meghe), Wardha- 442001, Maharashtra, India.*

Authors' contributions

This work was carried out in collaboration between both authors. Both authors read and approved the final manuscript.

Article Information

DOI: 10.9734/JPRI/2021/v33i46A32900

Editor(s):

(1) Dr. Farzaneh Mohamadpour, University of Sistan and Baluchestan, Iran.

Reviewers:

(1) Papadatu Carmen-Penelopi, Dunarea de Jos University, Romania.

(2) Soroush Soltani, Universiti Putra Malaysia, Malaysia.

Complete Peer review History: <https://www.sdiarticle4.com/review-history/74175>

Mini-review Article

Received 15 July 2021

Accepted 21 September 2021

Published 18 October 2021

ABSTRACT

Early childhood caries commonly affects the primary maxillary anterior teeth, in which extensive post- endodontic rehabilitation has always been a challenge. This is due to the small size of the crown, relatively large pulp chambers, and the age of the child. The remaining inadequate sound tooth structure renders restorations more prone to fractures. Among the available treatment modalities which include extraction of the grossly destructed tooth structure, use of semipermanent crowns and intracanal posts, the posts can be used effectively, to restore the lost function and anatomy. They also enhance the quality of the final coronal restoration by providing additional support for retention. The available methods for intracanal reinforcement for anterior teeth include the metal posts fabricated using orthodontic wires, short composite posts fabricated directed in the primary root canal, prefabricated glass fiber posts and posts utilising polyethylene fibers (Ribbond). Recently certain advanced techniques such as the biologic dentin and zirconia have also come into use. The various advantages and disadvantages for these have been summarised in this review along with the standardised clinical protocol for their placement in the primary root canals. Various in-vivo and in-vitro studies have concluded that the glass-fiber short intracanal posts provide the most suitable esthetics, strength, elastic modulus, and resilience. However, further qualitative research is required to certify it as a standard treatment modality.

*Corresponding author: E-mail: rashi.sriv@gmail.com;

Keywords: Primary teeth; dental caries; post and core technique; dental esthetics.

1. INTRODUCTION

One of the most common diseases seen in children worldwide is dental caries [1]. High sugar and starch consumption, irregular and improper maintenance of oral hygiene and feeding practices, genetic predilection and salivary composition are some of its predisposing factors [2]. Owing to the large population base, and lack of knowledge pertaining to oral health care, [3] these lesions are often left untreated. This leads to pain and extensive loss of tooth structure, eventually resulting in the breakdown of the oral and physical functionality of the child [4].

Often this may result in premature loss of teeth. Primary incisors with extensive caries may cause speech defects by altering the pronunciation of some consonants and sibilants. The disease further decreases masticatory efficiency and may even lead to the development of abnormal tongue thrusting habits which subsequently result in malocclusion. The resultant compromised esthetics in children may also raise serious psychological issues [5].

Early childhood caries is one of the most debilitating conditions seen in young children and it commonly affects the primary maxillary anterior teeth, in which extensive post- endodontic rehabilitation has always been a challenge. This is due to the small size of the crown, relatively large pulp chambers, and the age of the child. The remaining inadequate sound tooth structure renders restorations more prone to fractures [6]

Over the last few decades, various treatment strategies have been introduced such as, crowns for the coronal restorations, made of polycarbonate, cellulose strip crowns, art glass crowns, as well as veneered stainless steel crowns. Although it was found that in cases with

severe carious loss of tooth structure, these restorations could not successfully withstand the occlusal forces [7].

Posts can be used in such teeth with severe decay effectively, to restore lost function and anatomy. In addition to intra-coronal restoration, they also enhance the quality of the final coronal restoration by providing additional support for retention [8]. In primary teeth the procedure for achieving this intracanal retention for restoration of the mutilated or grossly decayed anterior teeth is delicate. It requires a standardized treatment protocol which is less time consuming, and allows ease of fabrication with minimal chairside time as well as isolation. Thus, the selection of the material depends on the clinicians expertise, and the conditional requirement of the individual teeth. The intracanal posts should also be designed, so as to allow unimpeded shedding and timely eruption of the permanent successors.

Myriad methods have been used with additional permutations and combinations for intracanal reinforcement for anterior teeth, namely wire posts, Ni-Cr coil spring posts, metal screw posts, short composite posts, [9,10] prefabricated glass fiber posts and posts utilising polyethylene fibers (Ribbond). The various treatment options have been discussed in this review along with their advantages and disadvantages to aid in the selection of the appropriate technique for the clinicians.

1.1 Classification of Posts which are Used in Primary Teeth: [9]

Post systems for primary teeth can be classified based on the design of the post space, materials used, design of the posts and their methods of fabrication as being presented in Figs 1-4:

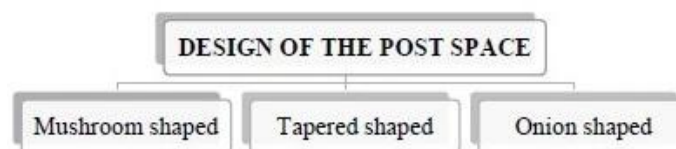


Fig. 1. Classification of Posts based on design of post space

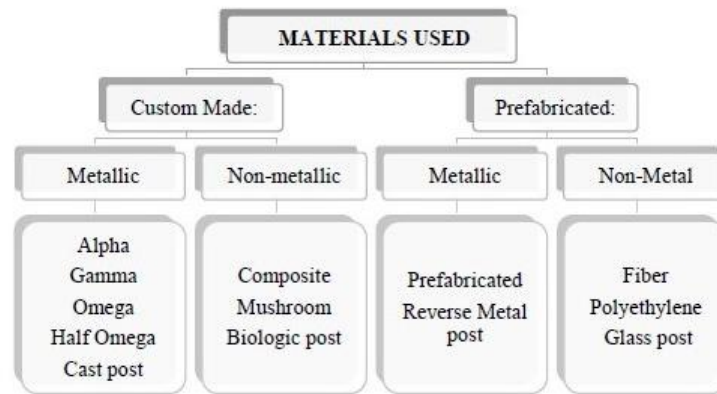


Fig. 2. Classification of Posts based on materials used

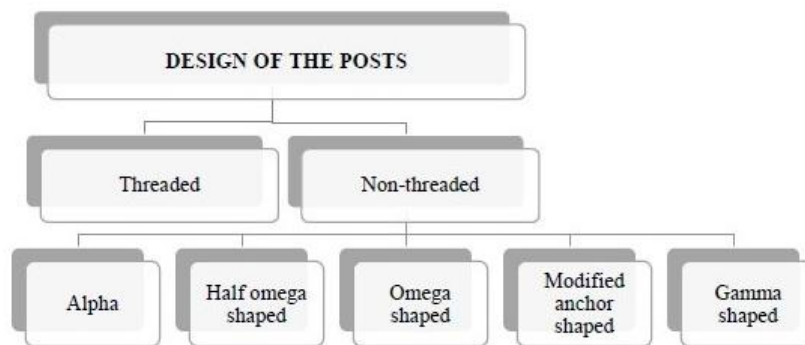


Fig. 3. Classification of Posts based on design of posts

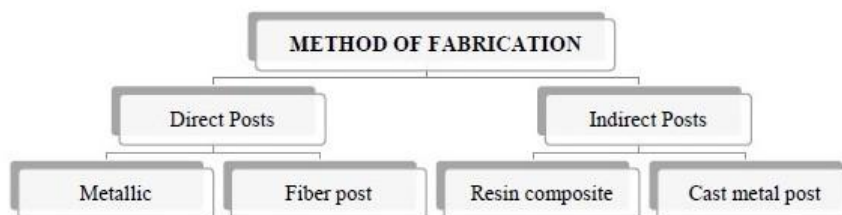

Fig. 4. Classification of Posts based on method of fabrication

1.2 Ideal Properties of Posts

- Resorbability to facilitate the eruption of permanent successor
- Post should adapt passively to the inner dentinal wall
- Biocompatibility
- Must be easily applied and available commercially
- Optimum refractive index to restore esthetics
- Adequate mechanical properties to withstand stresses of mastication

1.3 Posts Used in Pediatric Dentistry

The contemporary posts used in clinical practice have been summarised as follows: Metal orthodontic wire posts, cast metal posts, glass and carbon fiber posts, polyethylene fiber posts, and zirconia posts.

1.4 Metallic Posts

First introduced in 2004 by Mortada and King, the metal posts are fabricated using orthodontic stainless steel wire of 0.7 mm/ 22 gauge [9]. The

first design to be introduced was the "Omega post" which has both free ends embedded inside the canal. In "Half omega" and "Alfa posts", the stainless steel wire is bent to half omega and alfa shape respectively to potentially increase the surface area for attachment of the restorative material [10].

To further increase intracoronal retention, a 0.6-mm wire was shaped into the Greek letter "gamma" forming the "Gamma Post". The loop of the post is fitted in the intracanal space, and the remaining free ends are left projecting in the coronal portion of the tooth.

To overcome the problems pertaining to retention as seen with omega posts a modified anchor-shaped post was introduced. Both arms of the wire are bent downwards and subsequently turned to the opposite side. The free end of the arms is bent towards the curved end and compressed. This causes the free ends to open up, which adapts to the walls of the root and thereby provide additional mechanical retention. Another technique involves the placement of "mushroom-shaped" retention grooves. These are placed on the inner side of the root to create a locking mechanism, further increasing the retentive capacity [11].

Advantage: The metallic posts are easily customised and can be fabricated in-situ for each patient. They are cost effective and their unique designs allow for favourable retention *In vivo*.

Disadvantage: Orthodontic wire posts do not adapt adequately to the internal walls. This leads to the dislodgement of the wire [9]. The transmission of stresses from post to tooth structure is unfavourable and leads to decementation of the posts. The metal posts have a high modulus of elasticity, which leads to more chances of dislodgement of the post or even cause fracture of the tooth.

1.5 Composite Posts

This technique was first reported in 1986, [12] and involved the fabrication of the composite short posts directly into the post space by using composite resin. Later modifications were made where an orthodontic wire was incorporated into the short composite build-up. Mittal et.al. [13] also compared a technique where instead of the conventional two-step technique, a single monolithic unit consisting of composite crown and post was fabricated. Certain techniques included fabrication of composite posts by indirect method. The extraoral curing of the

composite resin can minimize the disadvantages of direct composite restorations although it is not in use for primary teeth.

Advantages: These posts provide satisfactory esthetics by use of tooth-coloured material. One of the major advantages of this technique is saving the chairside time, thereby overcoming the drawbacks of an uncooperative child with a short attention span.

Disadvantage: The retention of these composite short posts has a questionable prognosis due to the occurrence of polymerization shrinkage of the resins [9]. Commonly seen at the cervical cavosurface margins, exposure due to shrinkage causes failure and debonding of the restoration. Certain points of concern for these posts also include improper contact points/surfaces and relatively low wear resistance of the material [13].

This lead to the use of Fiber posts in primary teeth as the mean tensile strength values for glass fiber posts was statistically highest, followed by orthodontic wire posts and composite posts.

1.6 Fiber Posts

Fiber Reinforced Composite posts are made of carbon, quartz, or glass fibers, embedded in a matrix of epoxy or methacrylate resin [13] First evidence of a published article on the dental fiber posts was in 1990, by Duret et al.

- **Carbon fiber posts** were the initial fiber posts that consisted of unidirectional and continuous fibers of carbon/ graphite embedded in an epoxy resin matrix.

Advantages: These posts portray good mechanical properties, such as high tensile strength, the conductivity of electricity, stiffness as well as comparatively lower toxicity.

Disadvantages: Failure to provide the optimally esthetic results, even by utilization of all-ceramic restorations.

- **Silica Posts:** They are made from quartz fiber, which is pure silica in a crystallized form

Advantages: Provide better esthetic results than carbon fiber posts. Manufacturers suggest that utilisation of these posts, imparts similar biomechanical properties as carbon- fiber posts.

- **Glass fiber posts:** These posts contain different types of glass fibers, such as E-glass (electrical glass), and S-glass (high-strength glass)- which is preferred out of the two, owing to its higher moisture tolerance and modulus of elasticity.

These continuous glass fibers are oriented parallel to the longitudinal axis of the post and their diameter ranges between 6 -15 μm . A highly cross-linked structure binds these fibers and they are evenly distributed in a polymer matrix (commonly epoxy resin). This alignment allows the distribution of stresses over a broad surface area [14].

The adhesion between quartz or glass fibers prior to embedding them in a resin matrix is enhanced by fiber silanization.

The fiber posts are available in various shapes such as cylindrical, conical, cylindro-conical and double-tapered. Upon comparison of the parallel-sided posts with tapered dowels, the parallel sided posts are found to be more retentive [15].

Advantages: Compared to all the other posts, they are more aesthetic and impart strength to the mutilated tooth. Glass fiber reinforced posts are characterised with a modulus of elasticity which is approximately 20 GPa. Whereas, ceramic posts show a modulus of elasticity = 150 GPa, prefabricated metal posts and cast metal alloy posts have a modulus of elasticity about 200 GPa. Thus, the fiber reinforced posts have mechanical properties which are similar to that of natural dentin, which has a flexural modulus of about 18 GPa [16].

Disadvantages: The most common mode of failure noted with fiber posts in primary teeth is dislodgement post due to adhesive failures between the luting cement and root canal walls [17] followed by core failure. This can be attributed to the higher ratio of luting cement: post in the wide pulpal canals and chambers. Both these are classified under favourable modes of failure and may be re-restored however, they increase chairside time and expense to both the clinician and patients.

1.7 Alternative Techniques for Intracanal Rehabilitation

Polyethylene Fiber Posts:

Polyethylene fibers with ultra-high molecular weight are coated with a dentin bonding agent, and are used to build-up the endodontic posts

and cores. The fibers are adapted to the root canal and thus, canal enlargement is not required even for its use in permanent teeth [18]. The woven pattern of polyethylene fibers obtain a modulus of elasticity similar to the dentinal tissues. The resultant system creates a dentine-post-core mono-block as the luting resin is also incorporated in the monolithic structure. This improves the impact strength, flexural strength and modulus of elasticity, with a favourable stress distribution along the root.

Clinical trials have evaluated the rate of debonding in primary teeth and found excellent clinical performance even after 25 years in primary anterior teeth after pulp therapy [19].

Advantages: On comparison with other fibers, they are almost invisible in the resinous matrix. Hence, they allow the composite shade to reflect through making them the most appropriate and superior esthetic strengtheners of composite resin restorative materials.

Disadvantages: Core failure due to adhesive failures and low compressive strength of the flexible post material resulted in the lower mechanical stability of this technique of post and core.

Upon comparison of in-vivo comparative studies between glass fiber posts and polyethylene fiber posts, Mehra et al [6] and Sawant et al. [20] found clinical superiority and retention with primary anterior teeth restored with glass fiber posts making the Glass-fiber posts the most recommended technique for rehabilitation of primary teeth.

Zirconia Posts:

Zirconia posts were first introduced by Meyenberg et al, who reported that the flexural strengths (900–1200 MPa) of these posts were comparable to cast gold or titanium. These posts could be fabricated to the same dimensions as cast gold alloys or titanium as well. The high initial strength and fracture toughness of partially stabilized zirconia crystals stem from a physical property known as “transformation toughening” and is one of its most unique properties.

Various studies have been carried out to compare the physical properties and have been summarised by Özkurt et al. [21] who found that although the mechanical properties are ideal, little consensus with regard to their reliability is

available. Hence the factors which would contribute to their optimal application performance need to be evaluated for their use in primary teeth.

Advantages: High flexural strength and fracture toughness, chemical stability, biocompatibility and favourable optical properties are advantageous characteristics of zirconia as a restorative material.

Disadvantages: When used for endodontic posts, zirconia has revealed limitations in relation to its rigidity and difficulty in retrievability. This makes these posts more prone to cause root fractures than fiber posts. The surface of zirconia posts does not bond to resin composite materials.

Biologic Posts:

Although the concept of “Biologic restoration” was introduced in 1991 by Santos & Bianchi(12), Ramires-Romito et al in 2000, used natural teeth

and their subparts available at the Human Tooth Bank of Sao Paulo University Dental School as posts and crowns to fit into the roots and replace the crown structure of the existing tooth respectively [22].

Previously, the dentin posts have been prepared using primary root dentin while premolar root dentin was also be used. The premolars, being the most commonly extracted tooth for orthodontic purposes, are available widely and another advantage of using these is ease of finding them in sound form. However, the primary tooth dentin has a limited availability as primary teeth undergoing extractions have resorbed roots.

Advantages: One of the prime factors to be borne in mind while selecting the appropriate intracanal posts are biocompatibility, ease of applicability, and availability with a requirement for lesser chairside time. Dentine post/post with core has all these characteristics and an additional advantage of being inexpensive.

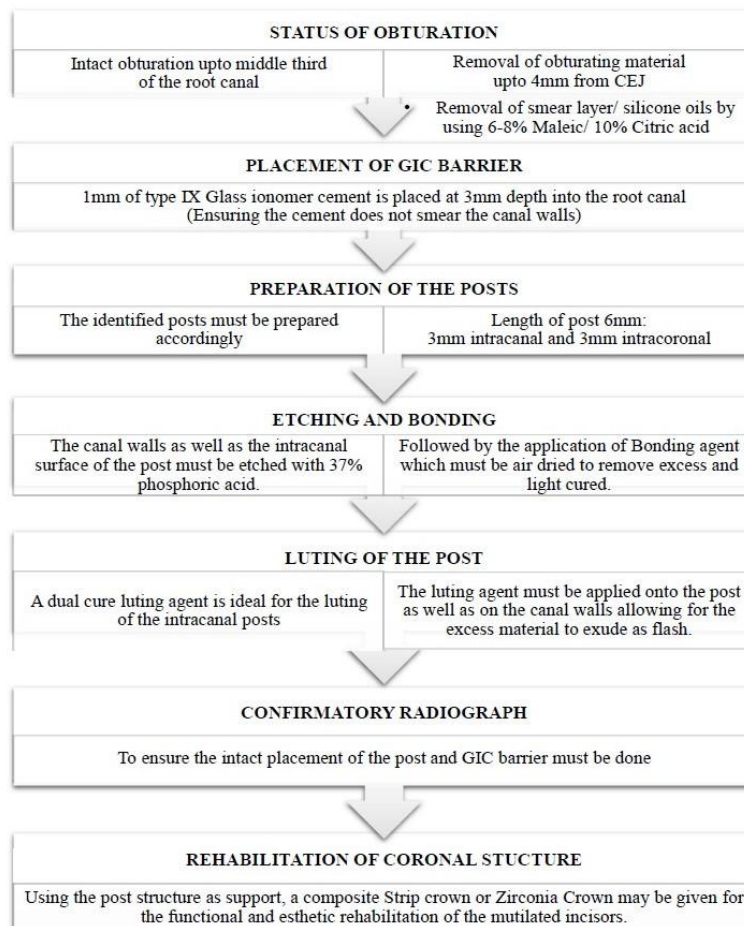


Fig. 5. Clinical Procedure for placement of post and core in primary teeth

Table 1. Modified USPHS criteria for direct clinical evaluation of clinical restorations

SCORE	Surface Texture	Anatomical form	Marginal Integrity (enamel)	Marginal discolouration (enamel)	Secondary caries	Gingival inflammation	Restoration Colour stability
Alpha	Sound	Sound	Sound	None	None	None	No change
Bravo	Rough	Superficial loss of material (Chipping, clefts)	Positive step, removable by finishing	Slight discolouration, removable by finishing	Caries present	Slight	Change of colour compared to baseline
Charlie	-	Strong and profound loss of material	Slight negative step not removable by finishing	Discolouration, localized not removable	-	Moderate	-
Delta	-	Total or partial loss of bulk	Strong negative step in major part of margin not removable by finishing	Strong discolouration in major part of margin not removable	-	Severe	-

Table 2. Extension for post and core restorations

SCORE	Post	Root	Periapical Status
Alpha	In situ with no gap between post and root canal obturating material or post and cavity walls	No clinical or radiographic sign of root fracture	Normal: good periapical condition
Bravo	gap between post and root canal obturating material or post and cavity walls	Root fracture, with bone loss next to root surface and pain on biting	Widening of the periodontal ligament (PL) not exceeding twice the width of the lateral PL
Charlie	Post displacement or detachment	-	Periapical radiolucency in connection with the apical part of the root, exceeding at least twice the width of the lateral PL
Delta	Post fracture	-	-

Disadvantages: One of the limitations of using biologic restorations is preoperative preparation, such as sterilization and preparation of the natural tooth to make dentine post/post and core/shell crown [12].

1.8 Standard Clinical Procedure

Upon reviewing various studies and previously published reviews, [12] the following summarization of the procedure for post and core in primary anterior teeth has been proposed in Fig. 5.

1.9 Follow-Up Evaluation

Follow-up is vital to determine the longevity of the primary posts. Ideally, the evaluation must be done until the tooth naturally exfoliates, to determine a successful treatment outcome. However, the available literature of in-vivo studies shows a maximum of 24 months follow-up.

The following criteria may be considered as a standard for measuring the various parameters for rehabilitation using primary posts. The Modified USPHS criteria has been given by the United States Public Health Services department for direct clinical evaluation of clinical restorations(6) and are presented in Table 1.

This criteria was further extended for post and core restorations as follows in Table 2.

2. CONCLUSION

A number of techniques exist for the rehabilitation of grossly mutilated maxillary primary anterior teeth, each having its various

advantages and disadvantages. The glass-fiber short intracanal posts provide the most suitable esthetics, strength, elastic modulus and resilience. However, due to the lack of evidence based literature, a concrete treatment protocol cannot be devised and further qualitative research is required for the same.

CONSENT

It is not applicable.

ETHICAL APPROVAL

It is not applicable.

ACKNOWLEDGEMENTS

All authors have made substantive contribution to this manuscript, and all have reviewed the final paper prior to its submission.

COMPETING INTERESTS

Authors have declared that no competing interests exist.

REFERENCES

1. Seraj B, Ghadimi S, Estaki Z, Fatemi M. Fracture resistance of three different posts in restoration of severely damaged primary anterior teeth: An in vitro study. *Dent Res J.* 2015;12(4):372.
2. Jain S, Mehta J, Rathi N, Bane S, Thosar N, Baliga S, et al. Management of missing primary anterior teeth by using modified Groper’s appliance in Early Childhood caries- a case report. *DMIMS J Dent Res.* 2020;4(4):140–2.

3. Gupta S, Srivastava R, Baliga S, Thosar N, Ghavat C. An archetypal case report of child abuse and neglect- a dentist's perspective. *J Indian Acad Forensic Med.* 2020;42(3):234–7.
4. Malviya N, Reche A, Thosar N, Baliga S, Rathi N, Deolia S. Evaluation and correlation of feeding practices of mothers residing in rural population of Vidarbha region towards presence of early childhood caries in their children. *DMIMS J Dent Res.* 2021;5(1):15–20.
5. Ravi R, Rajesh R, Nama R, Alankrutha G, Nallabolu RR, Singh R. Root as a Novel Post and Core Material for Primary Teeth: A Case Report. *J Pharm Bioallied Sci.* 2020;12(Suppl 1).
6. Mehra M, Grover R, Pandit I, Srivastava N, Gujnani N, Gupta M. Management of grossly decayed primary anteriors using various intracanal post systems: A clinical study. *J Indian Soc Pedod Prev Dent.* 2016;34(3):199.
7. Kapoor A, Thakur S, Singhal P, Chauhan D, Jayam C. Esthetic rehabilitation of severely decayed primary incisors using glass impregnated fiber post as post and core: A treatment option. *Indian J Dent Sci.* 2017;9(3):198.
8. Jindal S, Jindal R, Mahajan S, Dua R, Jain N, Sharma S. *In vitro* evaluation of the effect of post system and length on the fracture resistance of endodontically treated human anterior teeth. *Clin Oral Investig.* 2012;16(6):1627–33.
9. Shah S, Bargale S, Anuradha KVR, Patel N. Posts in primary teeth-a sile for better smile. *J Adv Med Dent Sci Res.* 2016;4(1):7.
10. Srinivas NC, Jayanthi M. Post endodontic restoration of severely decayed primary dentition: A challenge to pediatric dental surgeon. *World J Dent.* 2011;2(1): 67–9.
11. Baghalian A, Ranjipour M, Hooshmand T, Herman N, Ebrahimi A. Comparison of fracture resistance in post restorations in primary maxillary incisors. *Eur J Paediatr Dent.* 2014;15(3):313–6.
12. Suwarnkar SD, Prasad VN, Khan R, Sirikonda S. Posts in primary teeth- a literature review. *J Interdiscip Dent Sci.* 2017;6(2).
13. Mittal N, Bhatia HP, Haider K. Methods of intracanal reinforcement in primary anterior teeth—Assessing the Outcomes through a Systematic Literature Review. *Int J Clin Pediatr Dent.* 2015;8(1):48–54.
14. Buschow KHJ, editor. *Encyclopedia of materials: Science and technology.* Amsterdam ; New York: Elsevier. 2001; 10.
15. Belli S, Eskitascioglu G. Biomechanical properties and clinical use of a polyethylene fibre post-core material. 2006;8(3):8.
16. Lamichhane A, Xu C, Zhang F. Dental fiber-post resin base material: a review. *J Adv Prosthodont.* 2014;6(1):60.
17. Migliau G, Piccoli L, Di Carlo S, Pompa G, Besharat LK, Dolci M. Comparison between three glass fiber post cementation techniques. *Ann Stomatol Roma.* 2017;8(1):29–33.
18. Goracci C, Ferrari M. Current perspectives on post systems: A literature review: Post systems. *Aust Dent J.* 2011;56:77–83.
19. Memarpour M, Shafiei F. Restoration of primary anterior teeth using intracanal polyethylene fibers and composite: An *In vivo* study. *J Adhes Dent.* 2012;15(1):85–91.
20. Sawant A, Chunawalla Y, Morawala A, S Kanchan N, Jain K, Rohan. Evaluation of novel glass fiber-reinforced composite technique for primary anterior teeth with deep carious lesions: A 12-month clinical study. *Int J Clin Pediatr Dent.* 2017;10(2):126–30.
21. Özkurt Z, Iseri U, Kazazoglu E. Zirconia ceramic post systems: A literature review and a case report. *Dent Mater J.* 2010;29(3):233–45.
22. Ramires-Romito A, Wanderley M, Oliveria M, Imparto J, Pires Correa M. Biological restoration of primary anterior teeth. *Quintessence Int.* 2000;35:405–11.

© 2021 Srivastava and Thosar; This is an Open Access article distributed under the terms of the Creative Commons Attribution License (<http://creativecommons.org/licenses/by/4.0>), which permits unrestricted use, distribution, and reproduction in any medium, provided the original work is properly cited.

Peer-review history:

The peer review history for this paper can be accessed here:
<https://www.sdiarticle4.com/review-history/74175>