



## The Cystoscope – An Alternative Choledochoscope for Open Operative Bile Duct Stones Localization and Removal

R. Gazdar<sup>1\*</sup>, P. J. Halder<sup>1\*</sup>, A. Boxwalla<sup>1</sup> and R. Kacheri<sup>1</sup>

<sup>1</sup>Department of Surgical Gastroenterology & HPB Surgery, Jagjivan Ram Railway Hospital, Mumbai, India.

### Authors' contributions

This work was carried out in collaboration among all authors. Authors RG and PJH did the review of literature and wrote the paper. Authors AB and RK were among the surgery team. All authors read and approved the final manuscript.

### Article Information

#### Editor(s):

(1) Prof. Arun Singh, Rohilkhand Medical College & Hospital, India.

#### Reviewers:

(1) Marcelo Moura Linhares, Federal University of Sao Paulo, Brazil.

(2) Rafal Al-Rawi, Hawler Medical University, Iraq.

Complete Peer review History: <http://www.sdiarticle4.com/review-history/66615>

Case Report

Received 23 January 2021

Accepted 30 March 2021

Published 08 April 2021

### ABSTRACT

**Background:** Large bile duct stones removal is a problem. It has been reported that the impact of open choledochoscopy for reducing the rates of missed stones after Common Bile Duct (CBD) stone clearance.

**Aim:** To highlight an alternative way to visualize the bile duct intraoperatively using a cystoscope as a choledochoscope.

**Case Presentation:** A 30-year-old female presented in the department of Gastrointestinal and Hepatopancreatobiliary Surgery, Jagjivan Ram Hospital, Mumbai Central, Mumbai, India with obstructive jaundice and cholangitis. She had a past history of laparoscopic cholecystectomy in the year 2013 and an open Common Bile Duct (CBD) exploration for stones in the year 2019. Recent imaging studies showed a large stone in the distal CBD. Endoscopic Retrograde Cholangiopancreatography (ERCP) stone removal and CBD stenting attempt was unsuccessful. During the Open CBD exploration (OCBDE), the stone had slipped into the left hepatic duct and was finally localized and removed using a cystoscope as a 'choledochoscope'. The cystoscope is a useful alternative for localization and removal of bile duct stones in the absence of a choledochoscope.

\*Corresponding author: E-mail: halderpj@gmail.com;

With this in mind, the case report also highlights the role of choledochoscopy for locating the slipped stone(s) and confirming stone clearance.

**Conclusion:** Cystoscope as a choledochoscope is useful for locating the slipped stones and preventing missed stones in OCBDE.

*Keywords: Large bile duct stones; choledocholithiasis; choledochoscopy; open bile duct exploration.*

## 1. INTRODUCTION

Large bile duct stones removal is a difficult problem [1,2]. While endoscopic removal is the most commonly used procedure, there is a high failure rate and alternative methods are required that are not available with most centers [3]. Surgical removal is the ultimate method for the removal of large bile duct stones.

The role of choledochoscopy after surgical Common Bile Duct (CBD) exploration has been emphasized by various authors to reduce the incidence of missed stones in the bile duct [4,5]. The aim of this case report is to highlight the utility of the cystoscope as a 'choledochoscope' after the open CBD exploration is completed as the available literature did not mention the use of a cystoscope as a substitute for the choledochoscope.

## 2. PRESENTATION OF CASE

A 30-year-old female presented with complaints of intermittent pain in the epigastric region, intermittent jaundice and fever with chills for the past one year. She had a past history of laparoscopic cholecystectomy in 2013 and an open CBD exploration for choledocholithiasis in 2019. At presentation, she was conscious and oriented, febrile but hemodynamically stable. She had icterus with right hypochondrium and epigastric tenderness but no lump or organomegaly. Blood analysis revealed a total leukocyte count (TLC) of 18,640/cu.mm, with 78% neutrophils. The total serum bilirubin was 6.8 mg/dl with direct bilirubin of 5.5 mg/dl, serum alkaline phosphatase (ALP) was 469 U/L, aspartate aminotransferase (AST) of 491 U/L, and alanine aminotransferase (ALT) of 469 U/L.

The Magnetic Resonance Cholangiogram (MRCP) showed moderate dilation of the intrahepatic biliary radicals (IHBR), bilateral hepatic ducts, CBD dilated 18 mm diameter, with terminal CBD narrowing and a stone measuring 22x8 mm in the lower CBD (Fig. 1). An endoscopic stone removal was

attempted, but cannulation of the papilla was unsuccessful and hence the procedure was abandoned and patient was referred for a surgical removal of the CBD stone.

The patient was taken up for an open CBD exploration with bilio-enteric anastomosis. After a choledochotomy was performed, no stone could be found in the lower CBD despite multiple attempts with forceful saline flushing and stone holding forceps applications. In the absence of a choledochoscope, it was decided to perform direct visualization of the biliary tree using a cystoscope as a choledochoscope. On cystoscopic visualization, no stone was seen in the lower CBD even after passing the cystoscope through the papilla into the duodenum. Hence the proximal bile duct was systematically inspected and finally the stone was found in the left hepatic duct near the confluence of segment 2 & 3 ducts (Fig. 2A). By sequentially crushing the stone using the cystoscopic biopsy forceps and forceful saline irrigation through the cystoscope, the stone was dislodged from the left hepatic duct (Fig. 2B) and finally removed through the choledochotomy (Fig. 3). Free bile flow was confirmed in the hepatic ducts by cystoscopic visualization. A side – to – side choledochoduodenostomy was performed.

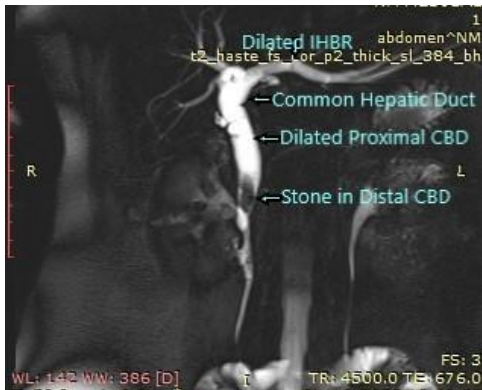
Post-operative course was uneventful and the patient is doing well in the subsequent post-operative follow-up. The post-operative imaging showed no residual stone in the bile duct.

## 3. DISCUSSION

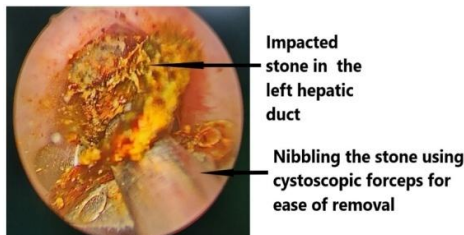
The definition of "Large" bile duct stones is not very clear. Many authors define a stone larger than 10-15 mm in diameter as "large" while others support that a stone with a diameter equal to the CBD diameter is a large stone [1,2].

An impacted large stone is the most frequent cause of ERCP failure (60%) [3]. Large stones (usually >15 mm) are more likely to be difficult to extract endoscopically. In cases where ERCP failed, CBD exploration will become a mandatory

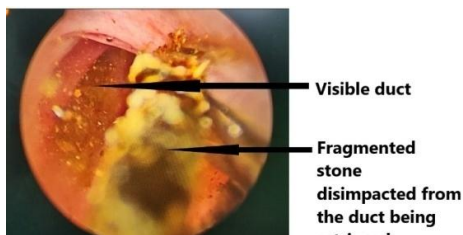
procedure [6]. Large difficult CBD stones can be managed either by open surgery or laparoscopically with acceptable outcomes with no need for multiple ERCP sessions due to their related morbidities. OCBDE with choledochoscopy is associated with higher stone clearance rate, shorter operative time, and post-operative stay [3].



**Fig. 1. MRCP**



**Fig. 2A. Choledochoscopy**



**Fig. 2B. Choledochoscopy**



**Fig. 3. Stone**

Mechanical lithotripsy, electro hydraulic lithotripsy, laser lithotripsy is performed using conventional mother-baby scope systems. Extra Corporeal Shock wave lithotripsy (ESWL), Endoscopic large balloon dilation (EPLBD), ultrathin cholangioscopes, thin endoscopes and ultimately the novel single use, single operator SpyGlass Direct Visualization System are some of the modern methods [3]. However, most of these facilities are not available in centres practicing standard and conventional ERCP procedures.

Open surgical approach is reserved for patients who have failed nonoperative treatments. Surgical management of large bile duct stones poses special problems for the surgeon [4]. The difficulty increases when previous open CBD exploration has been performed and the patient presents with a large CBD stone, obstructive jaundice and cholangitis as in our case [5]. The distorted anatomy, the adhesions due to the previous open surgery, the possibility of migration of the stone(s) into relatively inaccessible areas of the already dilated bile duct during intra operative manipulation of the duodenum and the bile duct are the added challenges to the surgeon.

In open CBD exploration, various methods to confirm the stone include direct palpation of the CBD ± duodenal mobilization by the Kocher's manoeuvre, flushing with saline, sounding of the stone with forceps, intraoperative cholangiogram, intra operative ultrasonography, and direct visualization of the bile duct (choledochoscopy) [5,7]. In this case, a pre-exploration intra operative cholangiography (IOC) was not attempted, as a preoperative MRCP was done. The other specialized techniques as mentioned above [3] were not available. The best option, therefore, was to directly visualize the bile duct and then remove the stone as stated by other authors [3,6,8].

Choledochoscope is not available in most centres. In our case, the cystoscope was used for direct visualization of the bile duct and removal of the stone. The purpose of this case report is to highlight an alternative way to visualize the bile duct intraoperatively using a cystoscope as a choledochoscope. A cystoscope is available in most of the modern operation theatres. It has a continuous irrigation system for obtaining a clear field and good magnification for visualization of bile duct. The biopsy channel can be used for passing forceps for holding and fragmenting the stone. With all

these advantages, we used it in the present case and were successful in removing the large stone in the left hepatic duct, a relatively difficult area to see, feel, and remove the stones. This also reduced the possibility of missed stone in our case in accordance with other authors. Gad et al [3], Ford et al. [9] and Desai and Shokouhi [7] detected better stone clearance rate when open choledochoscopy was used with clearance rates between 97% to 98% in their studies. Takada et al. [10] and Schwarz et al. [8] also found lower rates of missed stones with open choledochoscopy.

Shah and Clary [11] stated that retained CBD stones occur with higher frequency after positive CBD exploration than after a negative one and the rate of recurrence increases to approximately 20% after a second operation on the biliary tract for choledocholithiasis. Hence the need for a choledochoscopy is further emphasized.

To the best of our knowledge, we have not come across any literature of a cystoscope being used for removing large stone from the biliary tree. In a case reported by Öztürk et al. [12] who have indicated the retrieval of bilateral intrahepatic stones by percutaneous hepatolithotomy using cystoscope, but not through the bile duct.

#### 4. CONCLUSION

Removal of CBD stones can be sometimes dicey. This case serves as an example of a difficult situation when the stone is not found on open CBD exploration due to migration into the proximal bile duct or hepatic ducts where localization by palpation and visualization is difficult. A direct visualization of the bile duct and the hepatic ducts using the cystoscope as a choledochoscope should be kept in mind to avoid the possibility of missed stones in open CBD exploration.

#### CONSENT

As per international standard or university standard, patient's written consent has been collected and preserved by the author(s).

#### ETHICAL APPROVAL

There are no ethical issues. This is a case report in which the identity of the patient has not been revealed at any stage and no experiments have been conducted.

#### ACKNOWLEDGEMENTS

The authors thank Dr. Alap Mehendale, Visiting Urologist at Jagjivan Ram Railway Hospital for his expert assistance during the cystoscopic removal of the calculus.

#### COMPETING INTERESTS

Authors have declared that no competing interests exist.

#### REFERENCES

1. Carr-Locke DL. Difficult bile-duct stones: Cut, dilate, or both? *Gastrointest Endosc.* 2008;67:1053–1055.
2. Sharma SS, Jain P. Should we redefine large common bile duct stone?. *World J Gastroenterol.* 2008;14:651–652.
3. Gad E H, Zakaria H, Kamel Y, Alsebaey A, Zakareya T, Abbasy M, Mohamed A, et al. Surgical (Open and laparoscopic) management of large difficult CBD stones after different sessions of endoscopic failure: A retrospective cohort study. *Ann Med Surg (Lond).* 2019;43:52–63.  
DOI: 10.1016/j.amsu.2019.05.007
4. Chander J, Vindal A, Lal P, Gupta N, Ramteke VK. Laparoscopic management of CBD stones: An Indian experience. *Surg Endosc.* 2011;25(1):172-81.  
DOI: 10.1007/s00464-010-1152-5
5. Matsushima K, Soybel D I. Operative management of recurrent choledocholithiasis. *J Gastrointest Surg.* 2012;16(12):2312-7.  
DOI: 10.1007/s11605-012-1968-5
6. Panwar P, Reddy HM, Bagree R, Jalendra G. Experience with laparoscopic common bile duct exploration in failed endoscopic retrograde cholangiopancreatography cases at a tertiary care hospital. *Int Surg J.* 2020;7:3344-7.
7. Desai R, Shokhouhi BN. Common Bile duct stones, their presentation, diagnosis and management. *Indian J Surg.* 2009;71: 229–237.
8. Schwarz J, Simsa J, Pazdirek F. Our experience with preoperative choledochoscopy. *Ruzhl Chir.* 2007;86: 180–183.
9. Ford JA, Soop M, Du J, Loveday BP, Rodgers M. Systemic review of intra operative cholangiography in cholecystectomy. *Br. J. Surg.* 2011;99: 160–167.

10. Takada T, Yasuda H, Uchiyama K, Hasegawa H, Shikata J. Cholechochoscopy during biliary surgery for reducing the risk of overlooked stones. *Surg. Endosc.* 1991;5:192–195.
11. Shah KN, Clary BM. Stones in the bile duct: Clinical features and open surgical approaches and techniques. In: William R. Jarnagin, editors. *Blumgart's Surgery of Liver, Biliary Tract and Pancreas.* 6<sup>th</sup> Ed. Philadelphia, PA: Elsevier; 2017.
12. Öztürk A, Sönmez MG, BakdikSet al. New surgical technique applied with urological instruments in bilobar multiple hepatolithiasis: Ultra-mini percutaneous hepatolithotomy. *Turk J Urol.* 2017;43: 371–77.

© 2021 Gazdar et al.; This is an Open Access article distributed under the terms of the Creative Commons Attribution License (<http://creativecommons.org/licenses/by/4.0>), which permits unrestricted use, distribution, and reproduction in any medium, provided the original work is properly cited.

*Peer-review history:*  
*The peer review history for this paper can be accessed here:*  
<http://www.sdiarticle4.com/review-history/66615>