



Metastasis Relapse in Synovial Sarcoma of Parotid Gland Followed by Neuropathies and Tissue Damage: A Case Report

**Quratulain Babar ^a, Emmanuel Ifeanyi Obeagu ^{b*},
Chikwendu Lawrence Udenze ^c, Bart I. Ifionu ^d, C. C. N. Vincent ^e,
Chukwuma J. Okafor ^f, Emmanuel Ikechukwu Nwobodo ^g and C. O. C. Ibe ^{g,h}**

^a Department of Biochemistry, Government College University, Faisalabad, Pakistan.

^b Department of Medical Laboratory Science, Imo State University, Owerri, Imo State, Nigeria.

^c Department of University Health Services, Michael Okpara University of Agriculture, Umudike, Abia State, Nigeria.

^d Department of Chemical Pathology and Immunology, Olabisi Onabanjo University, Ogun State, Nigeria.

^e Department of Nursing Science, Imo State University, Owerri, Nigeria.

^f Department of Pathology and Biochemistry, State University of Zanzibar, Tanzania.

^g Department of Medical Laboratory Science, Evangel University, Akaeze, Ebonyi State, Nigeria.

^h Department of Medical Laboratory Science, Nnamdi Azikiwe University, Nnewi Campus, Nnewi, Anambra State, Nigeria.

Authors' contributions

This work was carried out in collaboration between both authors. Both authors read and approved the final manuscript.

Article Information

DOI: 10.9734/JPRI/2021/v33i54A33726

Editor(s):

(1) Dr. S. Srinivasa Rao, V. R. Siddhartha Engineering College, India.

Reviewers:

(1) Davor Tomas, University of Zagreb, Croatia.

(2) Mikaela Clotilde da Silva, State University of Paraiba, Brazil.

Complete Peer review History, details of the editor(s), Reviewers and additional Reviewers are available here:

<https://www.sdiarticle5.com/review-history/77254>

Case Report

Received 14 September 2021

Accepted 21 November 2021

Published 09 December 2021

ABSTRACT

Synovial sarcomas are a heterogeneous group of tumors, accounting for 1-2% of adult cancers worldwide. Formation of synovial sarcoma after tissue and nerve injury, radiations induced neuropathies and latent metastasis is those events which are still controversial and need more research. In this report, we present the case of an 18-year-old female patient who developed

synovial sarcoma followed by a punch to the face. MRI showed lobulated lesion of 4x3cm appreciated in left parotid space. In spite of Parotidectomy, radiotherapy and radiosurgery followed by MRI and CT-scan latent metastasis was raised in lungs which leads to demise of patient. There are numerous potential etiologic and neurological factors for the development of latent metastasis in synovial sarcoma. Here we will summarize all factors and its complications according to the current literature.

Keywords: *Synovial sarcoma; metastasis; tumor; soft tissues cancer; malignant; nerves; neuropathies.*

1. INTRODUCTION

Synovial sarcoma (SS) is a rare soft tissue tumor that occurs mainly in young adults. Synovial sarcomas arising in the head and neck region are well described, tumours actually originating in and around the major salivary glands are exceedingly rare, with few cases reported in the literature [1,2]. The disease-specific 5- and 10-year survival rates are 83% and 75% in children and young persons, respectively [3]. However, regardless of many reports in the past 100 years on traumatic events followed by development of soft tissue sarcoma, the causal linkage between the two occasions stays a controversy [4,5]. Recent work in laboratory animals shows a fundamental link between the formation of sarcoma which leads to severe tissue and nerve damage [6,7]. The trigeminal and facial nerves are the nerves that are most commonly affected in parotid gland tumors and are involved in perineural tumor spread (PNTS). PNTS along these nerves may result in facial pain, facial numbness and/or weakness of muscles supplied by these nerves [8]. Radiotherapy exposure can induce breakdown of cancer cells, causing the release of various cytokines and inflammatory mediators, and can also affect noncancerous cells. This inflammatory reaction causes fibrosis, atrophy, and ulceration of the related tissue, including vessels and nerves [8]. Through these events PNTS is promoted along with severe neuropathies. Metastatic relapse is observed in cancer patients with no clinical evidence of disease for months to decades after initial diagnosis and treatment [9]. Neuropathies and altered tumor microenvironment caused by radiotherapy and cancer cells plays an important role in latent distant metastasis and metastatic relapse in synovial sarcoma of parotid gland. We present a case in which a punch to the side of the face caused disruption of the parotid gland parenchyma and nerve injury which leads to synovial sarcoma, in spite of radiotherapy and radiations sessions distant latent metastasis and metastatic relapse was observed. Inflammation

on the spot, which changes into hard and very painful mass within 30 days. Through biopsy and MRI, it was revealed and diagnosed as synovial sarcoma of parotid gland.

2. CASE PRESENTATION

This case report is of a girl, diagnosed with Synovial sarcoma at the age of 18, and succumbed to cancer at the age of 21. On March 20, 2017 she was punched by her brother on lower left quadrant of her face (over left parotid gland) which lead to painful swelling of the gland in the next 2-3 hours. Events like weakness of facial muscles, numbness, and constant pain in parotid gland, swelling around jaw, difficulty in mouth opening and difference in shape of one side face were reflecting nerve damage. Within a month, swelling turned into a painful hard mass which gradually increased in size. Repeated FNAC showed signs of pleomorphic adenoma but on Parotidectomy, tumor was seen with deep roots. MRI showed Synovial sarcoma, very vascular, non-friable tumor (Fig. 1). After being diagnosed with Synovial sarcoma, patient was subsequently treated with 30 sessions of radiotherapy. On follow up, tumor was seen progressing aggressively. Since open surgery was not a favorable option, the oncologists decided to go for radiosurgery of the now invading tumor. After radiotherapy spontaneous persistent primary pneumothorax was observed in right lung. Patient was sent for cyber knife robotic radiosurgery in Jinnah Postgraduate Medical Centre JPMC, Karachi, Pakistan in December 2019 (Fig 5). Surgery showed good prognosis initially. Patient's CT scan, blood profile, X-rays was satisfactory and her body weight and general health was seen improving. On the morning of 17 June, 2020 patient experienced excruciating pain in her abdomen and was taken to Allied hospital, Faisalabad. X-rays and ultrasound reports showed pleural effusion along with multiple secondary tumors in abdomen, indicating metastatic pulmonary disease (Fig. 2) and (Fig. 3). With the passage of

time, health of the patient deteriorated, showing significant cachexia. On and off patient showed symptoms such as high fever, hemoptysis, haematemesis, bloody sputum, dyspnea and body aches, particularly arm and backache (Fig. 4). Unfortunately, after a time span of approximately 2 months, patient took her last breath following a cardiopulmonary arrest on 13th August 2020. Postmortem appearance showed sunken eyes, edematous hands, swelling of eye due to retinal vein occlusion and feet and petechial haemorrhages on lips and buccal mucosa. Further studies reveal that patient's mother and her maternal uncle were suffering from thyroid cancer and acute myeloid leukemia, respectively.

3. DISCUSSION

There are a few reports about soft tissue sarcoma which follows injury, surgical and other factors like accident and trauma [5]. It has become really challenging to find out link

between these factors and its confirmation. Because it can be due to the fact that repetitive injury on already existing mass leads to formation of cancer. But here we want to prove that punch on parotid gland leads to formation of Synovial sarcoma with soft tissue tumor on parotid gland. There are many studies related to lab animals in which it has been proved that issue injury leads to sarcoma formation. Based on a study of the injury site on the contralateral wing after being injured with the clip; sarcoma development takes place when chicken was subjected to Rous sarcoma virus injections. Results of this research were very interesting because in spite of presence of virus in the blood no tumor were found other than the site of injection [10-12]. Transgenic mice were subjected to ear tagging and tail clipping which showed overexpression of V-jun oncogene with formation of sarcoma [13-15]. In Rous sarcoma virus infected chick's inflammatory growth factor B (TGF-b) replace wounding into tumor development [12].

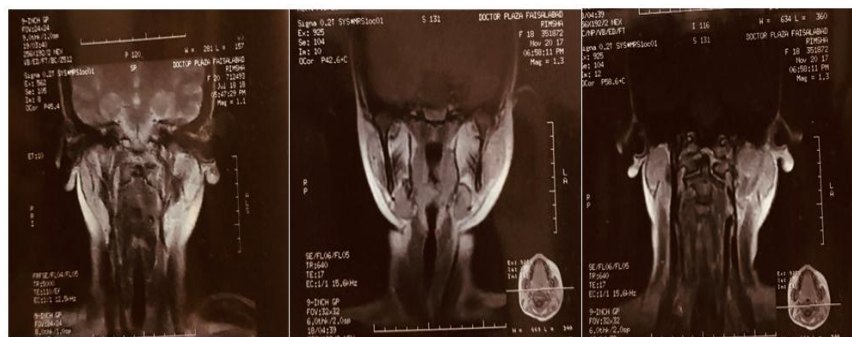

Fig. 1. Multiplanar, multisequential post contrast MRI; T1w and t2w hypointense signal lobulated lesion of 4x3cm appreciated in left parotid space involving deep part and is extending posteriorly between proximal part of sternocleidomastoid muscle and levator scapulae. Mass is showing post contrast enhancement and is abutting retromandibular vein

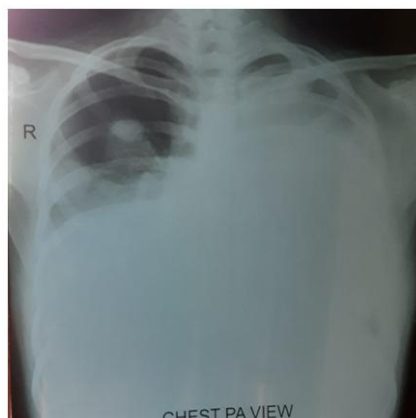

Fig. 2. Pneumothorax in right and left lung

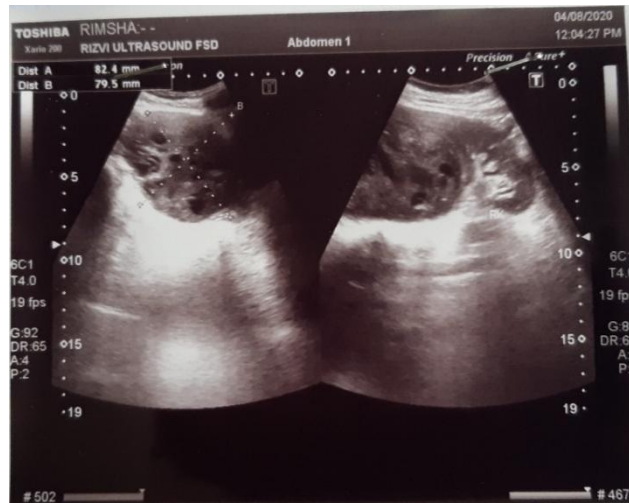

Fig. 3. Ultrasound of abdomen showing multiple tumours

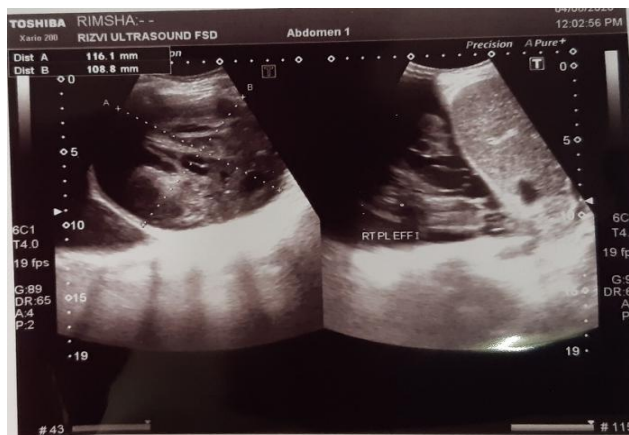

Fig. 4. Ultrasound of abdomen

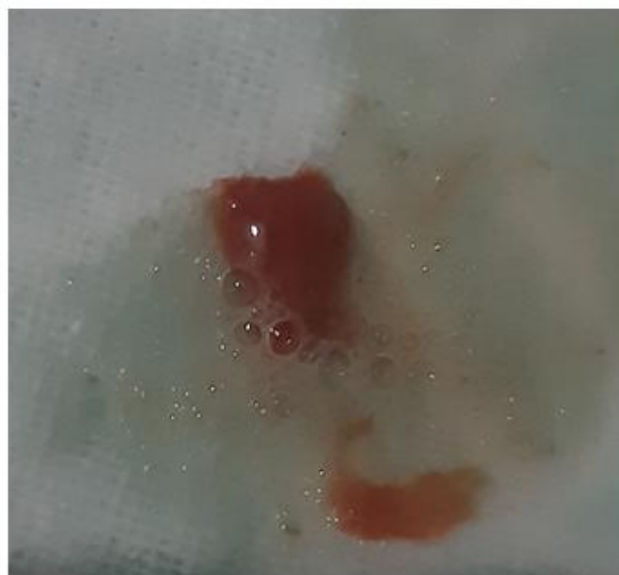

Fig. 5. Clots from sputum

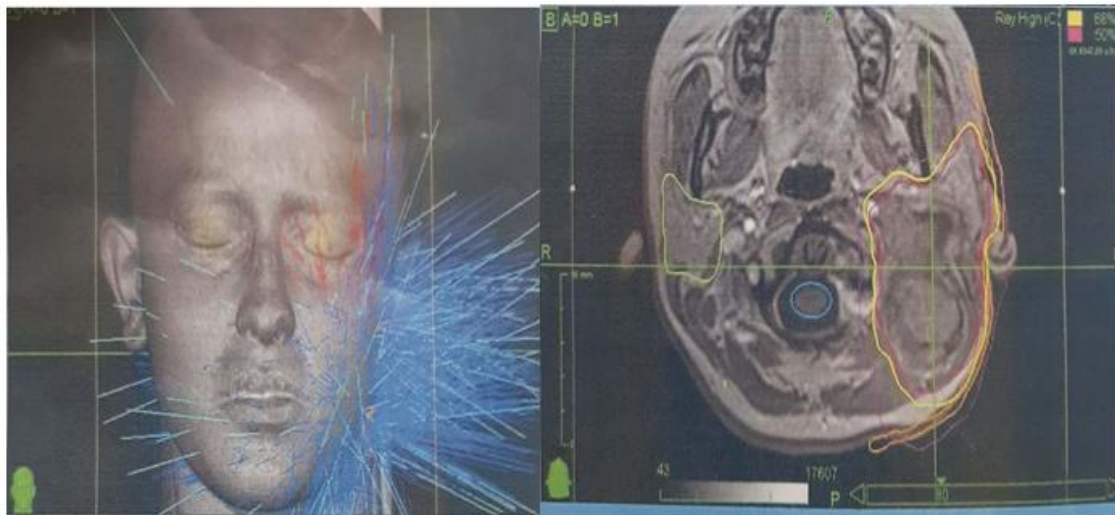


Fig. 6. Radiosurgery of synovial sarcoma of left parotid gland

There are many studies which emphasize on the link that muscle injury leads to sarcoma formation in mice due to genetic predisposition. In p53-null mice at the site of injury soft tissue sarcoma was formed by cardio toxin-induced muscle injury [6]. According to second study p53 null mice with activated kRAS proteins leads to formation of soft tissue tumor at the site of suture [16]. His aim was to get urothelial tumors in genetically predisposition mouse model. Finally, in 3rd study Mouse models having activated kRAS in muscle PAX7+ cells, along with p53 knockout profile was diagnosed with synovial sarcoma with soft tissue tumor at cardio toxin induced muscle injury site [7]. Interestingly there was no tumor formation take place when cardio toxin injection was administered all alone. Hence scientist proposed that injury act as promoter to drive sarcoma formation in patients having mutated oncogenes and other genetic factors [7].

To prove our linkage between injury and sarcoma formation we got help from already reported linkages between inflammation and tumor production [17-19]. We already know that in fibroblasts, lymphocyte, epithelial and endothelial cell several functional and phenotypic changes takes place for wound healing purpose when a cell is subjected to injury [20,21]. It is a dynamic process that involves tissue remodeling and cell proliferation of epithelial cells along with an inflammatory phase [22]. Chronic inflammation and inappropriate tissue remodeling occur without leaving the inflammatory stage [17,23]. Inflammatory cells like chemokines, growth factors and cytokines secrete

inflammatory mediators which causes chronic inflammation this leads to formation, progression and metastasis of tumor in sarcomas [21,22].

Lymphedema followed by soft tissue damage is another reason for cancer formation due to the punch. Lymphedema is due to pathological buildup of interstitial fluid in tissues. It is due to the failure of the lymphatic system to move lymph liquid from the tissues to the central circulatory system (CCS) and is showed clinically by tissue inflammation [24]. In few cases, lymphedema can be brought about by an unintentional wound to the lymphatic system. For instance, it can in some cases happen after a car crash where there's broad wounding or delicate tissue damage. Therefore, we claim that the blow causes inflammation, which in turn sets up tissue regeneration and healing of injury, but an uncontrolled healing process leads to cancer growth due to genetic factors. [25].

The trigeminal and facial nerves are the nerves that are most commonly affected in parotid gland tumors and are involved in Perineural tumour spread. Perineural tumour spread along these nerves causes facial pain, facial numbness and weakness of muscles supplied by these nerves. In addition, up to 40% of patients with Perineural tumour spread may be asymptomatic despite gross spread of disease on imaging and/or histopathology [8]. The tumor usually presents as a slow-growing mass and tends to spread along nerve sheaths [26]. Many types of tumors place the patients at significantly higher risk for progression and development of Perineural tumour spread (PNTS) [8]. Parotid

gland tumors are also one of them which promote metastasis through neurons. Metastasis through nerves are usually don't observed and diagnosed by MRI and CT-Scan. That's why it is important to evaluate and follow up nerve condition in Synovial sarcoma of parotid gland. Through these strategies we can reduce rate of metastasis and save patients from sudden death [27-29].

4. CONCLUSION

This case represents a linkage between soft tissue injury and development of soft tissue sarcoma. There are many reports on sarcoma formation by trauma but this work is totally emphasized on different aspects of sarcoma formation which includes injury, trauma, inflammatory process, regenerative process, genetic factors, disease complications and weak immune system. More work is required to prove strong link between soft tissue tumor formations with soft tissue injury. Injury act as promoter to drive sarcoma formation in patients having mutated oncogenes and other genetic factors. Nerve injury and neuropathies are very crucial in metastatic relapse by perineural tumor spread (PNTH). We can reduce rate of metastasis and save patients from sudden death by monitoring condition of nerve in parotid gland of synovial sarcoma.

CONSENT AND ETHICAL APPROVAL

As per international standard or university standard guideline Patient's consent and ethical approval has been collected and preserved by the authors.

COMPETING INTERESTS

Authors have declared that no competing interests exist.

REFERENCES

1. Jiang H, et al. A case of a 22-year-old man with primary synovial sarcoma of the parapharyngeal space with an ar somatic mutation: A clinicopathologic study and literature review;2021.
2. Sturgis EM, BOJCoio Potter. Sarcomas of the head and neck region. 2003;15(3): 239-252.
3. Eilber FC, SMJJoso Dry. Diagnosis and management of synovial sarcoma. 2008; 97(4):314-320.
4. Coley WB, NLJAos. Higinbotham, Injury as a causative factor in the development of malignant tumors. 1933;98(6):991.
5. Dijkstra M, et al. Soft tissue sarcomas of the head and neck associated with surgical trauma. 1995;109(2):126-129.
6. Camboni M, et al. Induction of a regenerative microenvironment in skeletal muscle is sufficient to induce embryonal rhabdomyosarcoma in p53-deficient mice. 2012;226(1):40-49.
7. Van Mater D, et al. Acute tissue injury activates satellite cells and promotes sarcoma formation via the HGF/c-MET signaling pathway. 2015;75(3):605-614.
8. Dankbaar, J.W., et al., Easily detected signs of perineural tumour spread in head and neck cancer. 2018;9(6):1089-1095.
9. Kim K, Marquez-Palencia M, Malladi SJFii. Metastatic latency, a veiled threat. 2019;10: 1836.
10. Dolberg DS, et al. Wounding and its role in RSV-mediated tumor formation. 1985; 230(4726):676-678.
11. Sieweke MH, et al. Mediation of wound-related Rous sarcoma virus tumorigenesis by TGF-beta. 1990;248(4963):1656-1660.
12. Martins-Green M, Boudreau N, Bissell MJJCR. Inflammation is responsible for the development of wound-induced tumors in chickens infected with Rous sarcoma virus. 1994;54(16):4334-4341.
13. Schuh AC, et al. Obligatory wounding requirement for tumorigenesis in v-jun transgenic mice. 1990;346(6286):756-760.
14. Schuh A, et al. Skeletal muscle arises as a late event during development of wound sarcomas in v-jun transgenic mice. 1992;7(4):667-676.
15. Shalaby F, Schuh AC, Breitman MLJO. Two distinct target cells for v-jun mediated wound tumorigenesis. 1994;9(9):2579-2588.
16. Yang X, et al. Simultaneous activation of Kras and inactivation of p53 induces soft tissue sarcoma and bladder urothelial hyperplasia. 2013;8(9):e74809.
17. Reim M, Grodau K, Kuhr MJEer. Proceedings: Hexokinase activity and corneal nutrition. 1975; 20(2):179-179.
18. Copie-Bergman C, et al. Proposal for a new histological grading system for post-treatment evaluation of gastric MALT lymphoma. 2003;52(11):1656-1656.
19. Lu H, Ouyang W, CJMcr Huang. Inflammation, a key event in cancer development. 2006;4(4): 221-233.

20. Werner S, Grose RJPr. Regulation of wound healing by growth factors and cytokines. 2003; 83(3):835-870.
21. Eming SA, Krieg T, Davidson JMJJolD. Inflammation in wound repair: molecular and cellular mechanisms. 2007;127(3):514-525.
22. Bar Y, Merimsky OJFio. Soft-Tissue sarcoma following traumatic injury: case report and review of the literature. 2017;7:134.
23. Radons JJCS. Chaperones, Inflammatory stress and sarcomagenesis: A vicious interplay. 2014;19(1):1-13.
24. Deng J, Wulff-Burchfield EM, Murphy BAJJM. Late soft tissue complications of head and neck cancer therapy: lymphedema and fibrosis. 2019;(53):lgz005.
25. Kuraishy A, Karin M, Grivennikov SIJl. Tumor promotion via injury-and death-induced inflammation. 2011;35(4):467-477.
26. Alvi S, Chudek D, Limaiem F. Parotid cancer;2019.
27. Nnatuanya IN, Obeagu EI, Obeagu GU, Nnatuanya CIC, Idem EE. Evaluation of Serum Haptoglobin in Fibroid Patients at Elele, Rivers State, Nigeria. J Gynecol Women's Health 2018; 8(4):555742. DOI:10.19080/JGWH.2018.08.555742
28. Nnatuanya IN, Obeagu EI, Obeagu GU, Nnatuanya CIC, Chukwudi EO (2017) Evaluation of serum cystatin C levels in fibroid patients in Elele. International Journal of Advanced Research in Biological Sciences 4(9): 101-103.
29. Ozims S, Agu G, Amah H et al. Prevalence of Prostate Enlargement among Males > 50 Years of Age Who were Treated at Abia State University Teaching Hospital, Aba from 2010- 2014. International Journal of Research Studies in Medical and Health Sciences. 2018;3(1):1-7.

© 2021 Babar et al.; This is an Open Access article distributed under the terms of the Creative Commons Attribution License (<http://creativecommons.org/licenses/by/4.0>), which permits unrestricted use, distribution, and reproduction in any medium, provided the original work is properly cited.

Peer-review history:

*The peer review history for this paper can be accessed here:
<https://www.sdiarticle5.com/review-history/77254>*