



Dental Evaluation Discloses Undetected Systemic Condition: A Case Report

V. Rajashekar Reddy ^{a++*}, A. Thirumagal Anuraaga ^{a#},
Tazyeen Saher ^{b†} and D. Madhusudan ^c

^a Department of Pedodontics and Preventive Dentistry, Sri Siddhartha Dental College and Hospital, Sri Siddhartha Academy of Higher Education, Tumkur, Karnataka, India.

^b Department of Pedodontics and Preventive Dentistry, Sharavathi Dental College and Hospital, Alkola, Shivamogga-577205, Karnataka, India.

^c Madhu Superspeciality Dental Care, Church circle, Tumkur, India.

Authors' contributions

This work was carried out in collaboration among all authors. All authors read and approved the final manuscript.

Article Information

Open Peer Review History:

This journal follows the Advanced Open Peer Review policy. Identity of the Reviewers, Editor(s) and additional Reviewers, peer review comments, different versions of the manuscript, comments of the editors, etc are available here: <https://www.sdiarticle5.com/review-history/98089>

Case study

Received: 01/02/2023

Accepted: 03/04/2023

Published: 11/04/2023

ABSTRACT

Aim: The significance of dental examination in identifying the underlying systemic condition.

Case Presentation: A 10 year old female patient reported with the complaint of pain since 1 week, also presence of milk teeth till this age. On Examination, short stature, macroglossia, retained deciduous teeth and delayed development of permanent dentition when compared with dental age and chronological age were revealed. Considering the clinical and radiographic condition thyroid dysfunction was suspected which is the second most common endocrine system glandular disorder, and it can manifest in any system of the body, including the mouth. Excess or deficiency of these

++Reader;

#Post Graduate Student;

†Senior Lecturer;

*Corresponding author: Email: drvrajashekarreddy@gmail.com;

hormones has a negative impact on the oral cavity. Based on dental features, we present this case of a child with undiagnosed hypothyroidism.

Conclusion: Hashimoto's disease is the common cause of hypothyroidism in children and adolescents. Since oral manifestations of hypothyroidism are uncommon, which may lead to incorrect diagnosis and subpar patient care. Therefore, it is important for the dentist to know the oral manifestations of systemic disease to promptly identify the underlying condition.

Keywords: Delayed eruption; hashimoto disease; hypothyroidism; dental examination.

1. INTRODUCTION

Thyroid disorder is becoming more common in this era. This rise can be linked to greater awareness and earlier identification of the condition. Many people in the general population have thyroid gland problems [1, 2]. According to certain statistics, the number of affected individuals may be twice as high as the amount of cases that go undiagnosed. Thus, patients with undetected hypothyroidism or hyperthyroidism are observed in the dental chair, where regular treatment may have detrimental consequences [2].

The most prevalent autoimmune disorder is Autoimmune Thyroid Disease (ATD), which affects 0.2% of men and 2% of women respectively [3]. The clinical manifestations of autoimmune thyroid disease (ATD) includes Graves' disease (GD) and the classic type of Hashimoto's thyroiditis (HT) [4]. The most frequent form of thyroiditis in children and adolescents is Hashimoto's thyroiditis (HT), also known as chronic lymphocytic thyroiditis. It is most commonly detected in females. The prevalence of the disease gradually rises with age and peaks in adolescence. HT is an organ-specific autoimmune condition. Environmental triggers such as stress, infection, iodine consumption, and vitamin D induces an immunological response through thyroid antigens in individuals who have a specific genetic susceptibility, promoting the onset of HT. Anti-thyroid antibodies against peroxidase (TPOAb) and/or anti-thyroid antibodies against thyroglobulin (TGAb) are indicators of HT, which is verified by typical thyroid ultrasonography findings [1,5].

The dental health care provider should be knowledgeable about the oral and systemic signs of thyroid dysfunction so they can identify any complications and evaluate how effectively the condition is managed. All elective dental procedures should be postponed until a thorough medical evaluation is completed if a patient's thyroid condition is suspected but has not yet

been detected [6]. Here, we describe a case of dental diagnosis of undiagnosed hypothyroidism in a 10 years old female patient.

2. CASE REPORT

A 10 year old girl came to the private clinic in Tumkur, Karnataka with the chief complaint of pain in her lower right and left back teeth region for past 1 week and also presence of all milk teeth till this age. Both of her prenatal and postnatal histories were insignificant. Extra oral examination revealed that she was short and overweight, there was hoarseness in her voice, puffy face and thick lips.

On Intra oral examination, Macroglossia with no evident of taste changes, type of dentition is deciduous dentition and dental caries in relation to 55,65,84,85,75, were noted (Fig. 1-2). Based on history and clinical findings, the provisional diagnosis was made as chronic irreversible pulpitis with relation to 85,75.

Panoramic radiography was performed following a clinical assessment. There were retained deciduous dentition and developing permanent tooth buds and erupting permanent first molars in all the quadrants suggestive of dental age 5.5- 6 years, which is contrary to the chronological age of the 10 year old child, suspecting the underlying systemic thyroid condition (Fig. 3). So patient was advised for further thyroid functions tests and it revealed, Anti Thyroglobulin Antibody level (Anti Tg) = 317.5 (Reference Interval = <4.11 IU/mL), Anti Thyro Peroxidase Antibodies (Anti TPO) = 73.00 IU/mL (Reference Interval = upto 34.0 IU/mL and Free T4 = < 5.15 pmol/L (Reference Interval = 10.3-25.80 pmol/L). Thus, her small stature, delayed eruption of permanent dentition, and delayed pubertal development were therefore attributed to hypothyroidism caused by Hashimoto's thyroiditis.

3. DISCUSSION

Up to 5% of females have thyroid function disorders. Compared to hyperthyroidism, it is 5 to 6 times more prevalent. Hashimoto's disease, radioactive iodine, surgery, and medications like

lithium and amiodarone are some of the main causes [7]. In our case it is due to Hashimoto's disease. It is a lymphocytic infiltration into the thyroid gland and the synthesis of autoantibodies against thyroglobulin and thyroid peroxidase. In this case, there was an elevated Anti Thyroglobulin Antibody level (Anti Tg), Anti Thyro Peroxidase Antibodies (Anti TPO), and low Free T4 which is suggestive of Hashimoto's Disease (Fig. 4). The new-borns appear normal at birth, but over the course of a few weeks, the clinical signs of hypothyroidism gradually emerge [8].

Congenital hypothyroidism is characterised by dwarfism, obesity, wide-set eyes, thick lips, a large, protruding tongue, frail muscle tone, pale complexion, stubby hands, delayed bone age, delayed tooth eruption, malocclusions, hoarse cry, an umbilical hernia, and mental retardation.

Few of the traits were present in our case also [7,9].

Because there is a decrease in the degradation of these molecules, more subcutaneous mucopolysaccharides, or glycosaminoglycans, are accumulating which causes the lips and tongue to thicken. The standard method for treating hypothyroidism is thyroxine replacement therapy (levothyroxine sodium). In the peripheral tissues, thyroxin (T4) is changed into triiodothyronine (T3), which has a higher metabolic activity. Patients are then returned to a biochemically normal thyroid state with normal TSH and serum-free T4 levels (FT). The patient's TSH and FT4 levels are monitored for intervals of six months to a year after reaching the euthyroid condition. Within 6 months of starting thyroxine therapy, our patient's levels of T3, T4, and TSH improved [7-10].

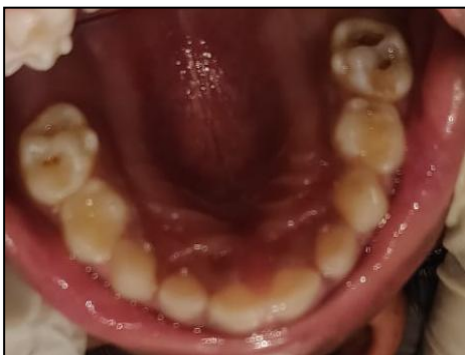

Fig. 1. Occlusal view of maxilla

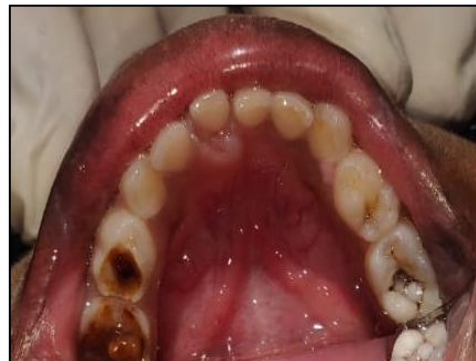

Fig. 2. Occlusal view of mandible

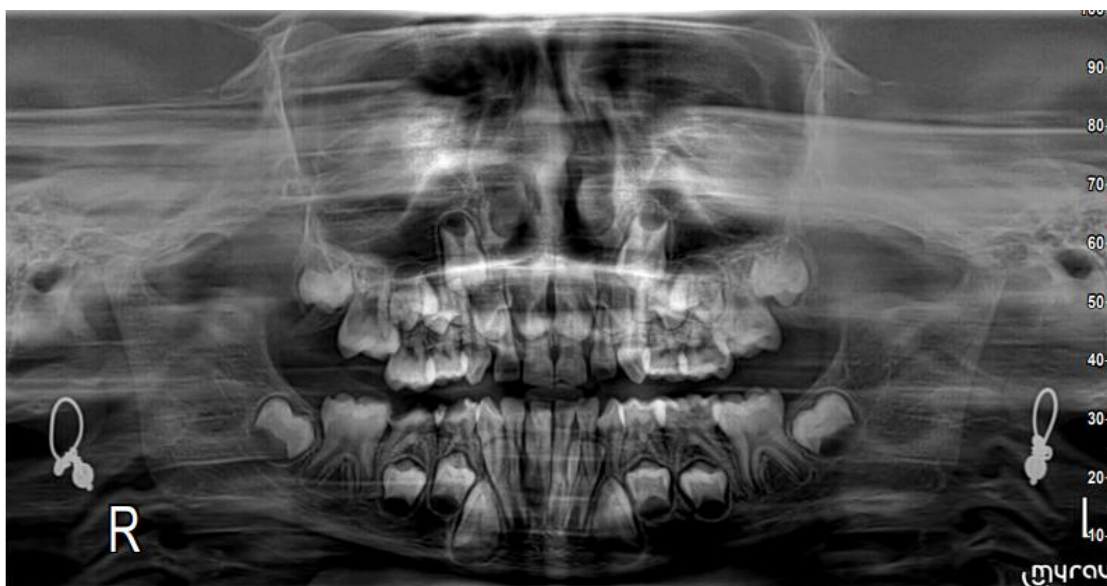


Fig. 3. OPG showing delayed development of permanent tooth bud

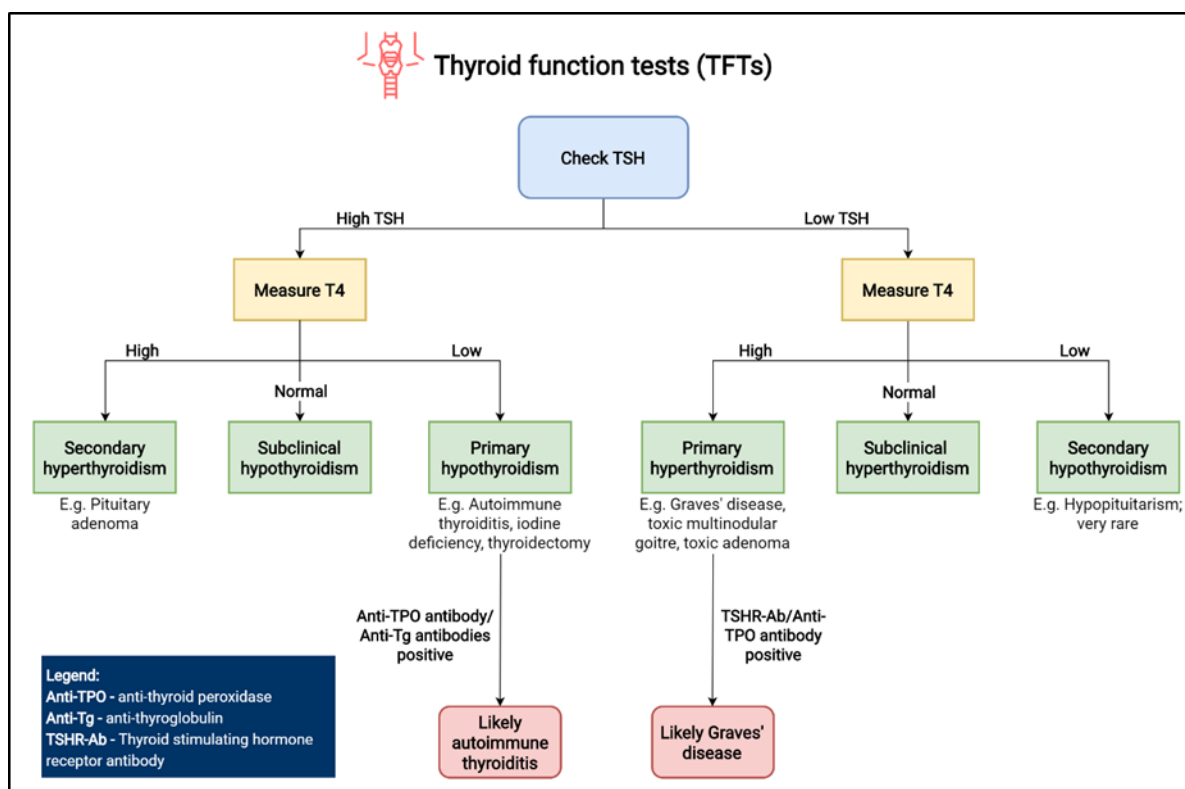


Fig. 4. Diagnosis chart for Hashimoto disease

For two reasons, a dentist must have a thorough understanding of thyroid disease and associated oral manifestations. First, the dentist might be the first to notice a serious thyroid condition and help with an early diagnosis. All elective dental procedures should be postponed if a patient's thyroid condition is suspected and a full medical examination is conducted before continuing dental procedures. The main complaint of our patient was tooth pain, but because we suspected hypothyroidism, we immediately referred her for diagnostics. Once the thyroid condition was under control, the necessary dental treatment was carried out.

The second justification is to prevent any potential dental issues that could arise when treating thyroid patients. If a patient has thyroid gland disease, dental treatment modifications must be taken into account. The usage of a thyroid collar by the dental professional while taking X-rays of a patient is one technique to safeguard the thyroid gland as it is very susceptible to radiation. Patients who suffer from a history of thyroid conditions should undergo a thorough evaluation to assess their degree of medical management and should be cared for in a way that reduces stress and

infection. The reduced metabolic activity of fibroblasts in hypothyroid patients may cause a delay in the healing of wounds. Due to the longer exposure of the unhealed tissue to pathogenic organisms, a delayed wound healing may be linked to a greater risk for infection. Also, hypothyroidism disrupts homeostasis [9]. Complicated dental procedures should be avoided to reduce the possibilities of adverse outcomes.

In this present scenario, systemic condition like Hashimoto's thyroiditis was diagnosed with the help of our routine dental examination. Similarly, condition like hypoparathyroidism which exhibits enamel hypoplasia (thin enamel), delayed eruption, and numerous unerupted teeth, microdontia, blunt ends of many roots and widened pulp chambers can also be found by using panoramic radiographs and routine dental examination [11]. Thus, close coordination with the endocrinologist is required if an urgent dental procedure is required during the first few weeks of thyroid medication. To safely and effectively treat thyroid patients, regular communication between the dentist and the endocrinologist is essential in patients with severe dental problems.

4. CONCLUSION

Dentists can play a vital role in identifying the dental patients with thyroid problems who haven't been properly diagnosed. In some situations, this could save a life, while in others, it could improve quality of life and prevent complications from some thyroid conditions. The endocrinologist should be knowledgeable with the oral symptoms of thyroid dysfunctions prior to treating a patient who has any thyroid disease. For the patient's oral and thyroid health to be maintained, there must be two-way contact between the dentist and the endocrinologist.

CONSENT

As per international standard, parental written consent has been collected and preserved by the author(s).

ETHICAL APPROVALS

As per international standard or university standard written ethical approval has been collected and preserved by the author(s).

COMPETING INTERESTS

Authors have declared that no competing interests exist.

REFERENCES

1. Tang S, Yang M, Zhang D, Tong YJ, Xin Y. Clinical characteristics and follow-up of 19 children with hashimoto's thyroiditis aged below 3 years: a single-center retrospective analysis. *Frontiers in Endocrinology*. 2021;12:1-8.
2. Cappa M, Bizzarri C, Crea F. Autoimmune thyroid diseases in children. *J Thyroid Res*. 2010;2011:675703.
3. Saravanan P, Dayan CM. Thyroid autoantibodies. *Endocrinology and metabolism clinics of North America*. 2001; 30(2):315-37.
4. De Luca F, Santucci S, et al. Hashimoto's thyroiditis in childhood: Presentation modes and evolution over time. *Italian journal of pediatrics*. 2013;39(1):1-3.
5. Gutch M, Anness B, Sukriti K, Arpit G, Rao SS. Macroglossia: An uncommon manifestation of primary hypothyroidism due to hashimoto's thyroiditis in a teenage child. *Journal of the ASEAN Federation of Endocrine Societies*. 2017;32(1):47-49.
6. Chandna S, Bathla M. Oral manifestations of thyroid disorders and its management. *Indian J Endocrinol Metab*. 2011;15(2): S113-6.
7. Dudhia SB, Dudhia BB. Undetected hypothyroidism: A rare dental diagnosis. *J Oral Maxillofac Pathol*. 2014;18(2):315-9.
8. Pinto A, Glick M. Management of patients with thyroid disease: Oral health considerations. *J Am Dent Assoc*. 2002; 133(7):849-58.
9. Singh G, et al. Dental management of patients with thyroid dysfunction. *J Res Adv Dent*. 2015;4:1s:190-196.
10. Park G, Song K, Shin HJ, Chae HW. Painful hashimoto thyroiditis in a 7-year-old girl: Differential diagnosis and medical treatment. *International Journal of Thyroidology*. 2021;14(1):50-4.
11. Mittal S, Gupta D, Sekhri S, Goyal S. Oral manifestations of parathyroid disorders and its dental management. *J Dent Allied Sci* 2014;3:34-8.

© 2023 Reddy et al.; This is an Open Access article distributed under the terms of the Creative Commons Attribution License (<http://creativecommons.org/licenses/by/4.0>), which permits unrestricted use, distribution, and reproduction in any medium, provided the original work is properly cited.

Peer-review history:
The peer review history for this paper can be accessed here:
<https://www.sdiarticle5.com/review-history/98089>